

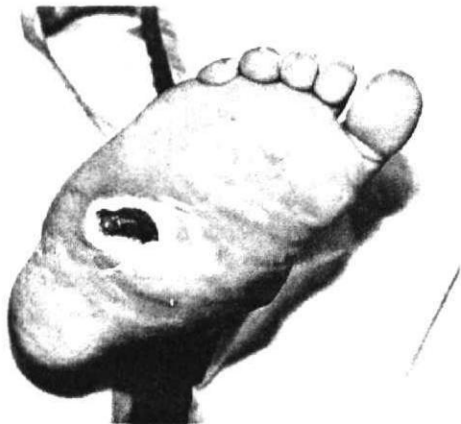Figure 3. At six weeks the hyperkeratosis was again reduced. This time wound depth was shallower and Hu' width was narrower. A clear sign of improvement was evident.

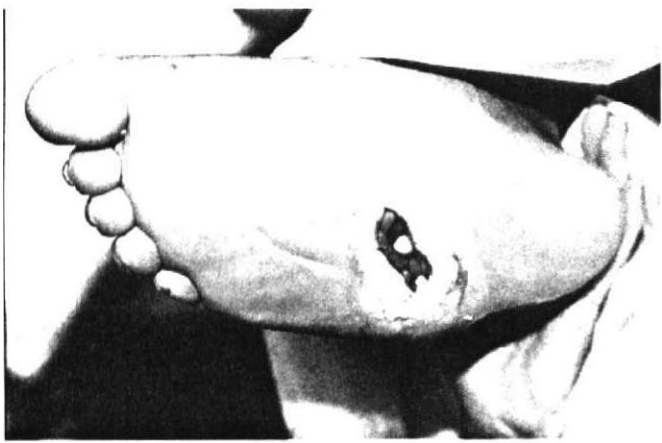


Figure 4. At nine weeks, the width of the zound was just less than lcin and looking healthy.

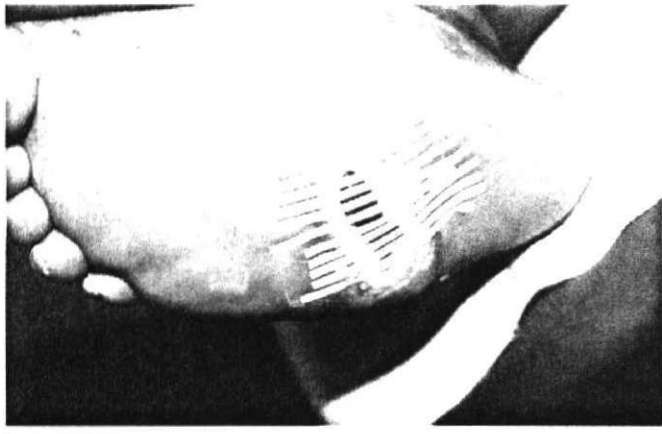

Figure 5. allow for better closure, Steristrips were applied to pull the wound together. However at ten weeks, the patient developed a thrombosis in his left thigh and this resulted in cardiac and bronchial complications. The hospital rest allowed the wound to close and a plastic surgeon performed a skin graft to close the zound.

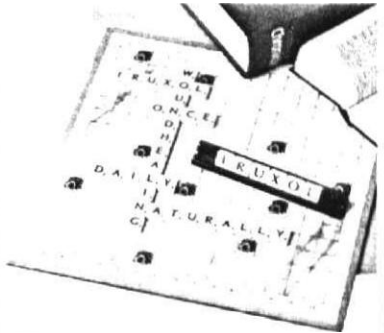
Uk

# mono ointment

TM MUT WIED

IUI WWIallak111111Z3

l 'Once daily treatment that works for both you itici your pmicni



Cleans necrotic tissue from the wound

Provides a clean base for wound healnig

Prevents ilk' adhesion of dressings to the wound surface

\* Rapid response - cost effectiveness

## FREE OFFER GIFT VOUCHER FROM EXCLUSIVE BOOKS WORTH R500

The first two correct entries drawn will receive a gift voucher from Exclusive Books worth R500 each.

Simply complete the section below and mail to: ii IF FIRS I' WORD IN WOUND HEALING.

PO Box 3030, Ialfway I louse, 1685.

Name: \_\_\_\_\_

Address: \_\_\_\_\_

Code: \_\_\_\_\_

Tel: \_\_\_\_\_

In which journal did this advert appear?

What issue? \_\_\_\_\_

What is the first word in wound healing?

L11 Iruxol mono ointment. Composition- Each 1g of writment columns \*(illagenase Clastridinpepidase A 1,20 units and Pi-incases 0.24 amus. RefNo. G 1633 (Act 10111965)

Knoll Pharmaceuticals  
South Africa (Pty)  
PO. Box 3030. Ilalfwax House. 1685

